



# Efficacy of Perflubutane Microbubble–Enhanced Ultrasound in the Characterization and Detection of Focal Liver Lesions: Phase 3 Multicenter Clinical Trial

Fuminori Moriyasu<sup>1</sup>  
Kouichi Itoh<sup>2,3</sup>

**OBJECTIVE.** The purpose of this study was to assess the efficacy and safety of contrast-enhanced ultrasound performed with perflubutane microbubbles in comparison with unenhanced ultrasound and dynamic CT in the characterization of focal liver lesions during the vascular phase of imaging and in the detection of lesions during the Kupffer phase.

**SUBJECTS AND METHODS.** A total of 196 patients were enrolled at 15 centers in Japan. Vascular phase images were obtained before contrast injection until 1 minute after injection. Kupffer phase images were obtained 10 minutes after injection. Dual-phase CT was performed as determined by standard clinical practice at each center. Unenhanced ultrasound, contrast-enhanced ultrasound, and CT images were read by blinded reviewers, and the results they reached regarding characterization and detection were compared with reference standard findings made by onsite investigators. The safety observation period was 72 hours after contrast administration.

**RESULTS.** Among the 190 patients included in the characterization analysis, the accuracy of contrast-enhanced ultrasound (88.9%) was significantly greater than that of unenhanced ultrasound (68.4%) and dynamic CT (80.5%) ( $p < 0.001$  and  $p = 0.008$ ). Among the 191 patients in the detection analysis, the efficacy of contrast-enhanced ultrasound in detection of lesions was significantly higher than that of unenhanced ultrasound and dynamic CT ( $p < 0.001$  and  $p = 0.008$ ), predominantly because more metastatic lesions were detected (both  $p < 0.001$ ). In particular, contrast-enhanced ultrasound was superior to dynamic CT in the detection of metastatic lesions measuring 1 cm or smaller. The incidence of adverse events was 49.2% and that of adverse drug reactions was 10.4%. All adverse drug reactions were mild.

**CONCLUSION.** Compared with unenhanced ultrasound and dynamic CT, contrast-enhanced ultrasound with perflubutane microbubbles improved diagnostic efficacy in both characterization and detection of focal liver lesions with no serious adverse drug reactions.

**Keywords:** characterization, detection, contrast-enhanced ultrasound, focal liver lesions, perflubutane

DOI:10.2214/AJR.08.1618

Received August 1, 2008; accepted after revision December 29, 2008.

Funding for this study was provided by Daiichi Pharmaceutical Company. Perflubutane microbubbles were provided by Amersham Health. Authors who were not employees of either sponsor controlled the inclusion of any data and information that might have presented a conflict of interest for employees of either sponsor.

<sup>1</sup>Department of Gastroenterology and Hepatology, Tokyo Medical University, 6-7-1 Nishishinjuku, Shinjuku-ku, Tokyo 160-0023 Japan. Address correspondence to F. Moriyasu (moriyasu@tokyo-med.ac.jp).

<sup>2</sup>Department of Clinical Laboratory Medicine, Jichi Medical School, Tochigi, Japan.

<sup>3</sup>Present address: Hitachiomiya Saiseikai Hospital, Ibaragi, Japan.

AJR 2009; 193:86–95

0361–803X/09/1931–86

© American Roentgen Ray Society

**C**ontrast agents for sonography are principally gas-encapsulated microbubbles. Successful efforts have been made to produce microbubbles that are sufficiently small and stable to pass into the systemic circulation after IV administration [1, 2]. Initially, the efficacy of commercially available air-based microbubble agents was limited because the bubbles were easily destroyed by ultrasound exposure [3–5]. With modification of the composition of the microbubble shell and use of a lower-solubility substance such as a perfluorochemical instead of gas, stability and resistance to pressure were improved [6, 7]. The critical improvement has been development of microbubble-specific imaging techniques that work at a low enough mechanical index to minimize destruction of microbub-

bles [8–10]. The development of perfluorochemical gas-encapsulated microbubbles and high-frame-rate real-time scanning for contrast-enhanced ultrasound (CEUS) enabled the study of early arterial events, leading to accurate diagnosis of liver lesions owing to visualization of the tumor vasculature and specific enhancement patterns [11–13].

The perflubutane microbubbles used in this study are perfluorochemical agents consisting of microbubbles of perfluorobutane (C<sub>4</sub>F<sub>10</sub>) stabilized by a monomolecular membrane of hydrogenated egg phosphatidyl serine [14]. When the liver is imaged in the phase-modulation harmonic mode, CEUS with perflubutane microbubbles has two phases of contrast enhancement: vascular and Kupffer phase. Vascular phase images are acquired soon after IV contrast injection and can be used to

## Ultrasound of Focal Liver Lesions

characterize selected lesions on the basis of the dynamics of contrast enhancement (e.g., arterial and portal venous), morphologic features of the tumor vasculature, and tumor perfusion [15]. Unlike contrast-enhanced Doppler imaging, CEUS in the phase-modulation harmonic mode is expected to depict microvessels because the mode does not cause the blooming that often occurs in Doppler imaging.

Perflubutane microbubbles are taken up by Kupffer cells in the reticuloendothelial system of the liver, and this phenomenon allows parenchyma-specific imaging of the liver [16–18]. Parenchyma-specific imaging, called Kupffer phase imaging, is typically performed 10 minutes after contrast injection, at which time the normal hepatic parenchyma is enhanced, and malignant lesions that contain few or no Kupffer cells are clearly delineated as contrast defects [15, 19]. Therefore, it is conceivable that Kupffer phase imaging can be used to detect focal liver lesions. The diagnostic performance of microbubble agents that can be used for both the vascular and parenchyma-specific, or Kupffer, phases of hepatic ultrasound has not, to our knowledge, been evaluated in a controlled clinical study. The purpose of this prospective open-label multicenter phase 3 study was to assess the efficacy and safety of CEUS with perflubutane microbubbles in the characterization and detection of focal liver lesions in the vascular and Kupffer phases of imaging, respectively, in comparison with unenhanced ultrasound and dynamic CT (DCT).

### Subjects and Methods

#### Patient Population

Before initiation, this study was approved by the institutional review boards at each of the 15 participating institutions. All patients provided written informed consent before entering the study. **The subjects were patients who had at least one untreated focal liver lesion** confirmed with a previous diagnostic study (e.g., DCT, contrast-enhanced MRI, angiography, pathologic examination). Inclusion criteria were the presence of a hepatic mass or lesion confirmed at DCT within the past month (past 3 months for benign tumors), fewer than 10 known lesions, and being a man or woman 20–80 years old.

The exclusion criteria were terminal clinical condition and life expectancy of 3 months or less; previous administration of perflubutane microbubbles; ongoing transcatheter chemotherapy or radiation therapy; current or within the past 180

days participation in another clinical study; pregnancy, possible pregnancy, or lactation; history of allergy to eggs or egg products; surgical procedure or liver biopsy within 24 hours before administration of perflubutane microbubbles; administration or scheduled administration of another contrast agent within 24 hours before or after administration of perflubutane microbubbles; difficulty in recognition of a target lesion previously determined with DCT or difficulty with a scan of the whole liver with unenhanced ultrasound owing to poor baseline image quality; and mass or lesion size 10 cm or greater.

Among 196 patients enrolled from April 2002 to March 2003, three patients were excluded from the study: Two did not receive perflubutane microbubbles and one had a good clinical practices violation. Of the 193 patients eligible for safety evaluation, 130 were men and 63 were women. The mean age was 63 years (range, 23–80 years). Among the 193 patients eligible to participate in the safety evaluation, 190 patients were eligible for evaluation of the efficacy of vascular phase imaging and 191 for evaluation of the efficacy of Kupffer phase imaging. One patient was excluded from the efficacy evaluation for not meeting the study recruitment criteria. In addition, two patients from vascular and one patient from the Kupffer phase imaging were excluded because they missed the video recording. The number of patients eligible for vascular phase imaging included 121 with hepatocellular carcinoma (HCC), 38 with metastatic lesions, 17 with hemangiomas, nine with other benign lesions, and five with other malignant lesions. One additional patient with a benign lesion was included in the evaluation of Kupffer phase imaging.

#### Contrast Agent

Perflubutane microbubbles (Sonazoid, GE Healthcare) is a lyophilized preparation reconstituted for injection and contains 16  $\mu\text{L}$  of perflubutane microbubbles in one vial. The contents of each vial were resuspended in 2 mL of water for injection. Each patient received a single injection of 0.12  $\mu\text{L}/\text{kg}$  of microbubbles (0.015 mL/kg of the reconstituted suspension) into a forearm vein followed by a 10-mL saline flush.

#### Ultrasound

All ultrasound scanners (Aplio, Toshiba Medical Systems; Elegra, Siemens Healthcare; EUB 8500, Hitachi; HDI 5000, Phillips Healthcare; Logiq 7, GE Healthcare; Sequoia 512, Siemens Healthcare) were equipped with broadband curved-array transducers adapted for contrast imaging. Ultrasound was performed before and after enrollment. Unenhanced ultrasound performed

before enrollment was used as a reference standard and to assess whether the subject met the inclusion criteria and fulfilled none of the exclusion criteria. Ultrasound imaging was performed after enrollment to compare the efficacy of CEUS with perflubutane microbubbles. In each patient, one lesion of interest, which had not been treated and was confirmed with DCT, was selected for vascular phase imaging for lesion characterization. The whole liver was scanned in the Kupffer phase for lesion detection. Unenhanced ultrasound images corresponding to both the vascular and the Kupffer phase images also were acquired for assessment by the blinded reviewers. All ultrasound images were acquired by onsite investigators according to the following imaging conditions and were recorded on S-VHS videotape for review by the blinded readers.

*Unenhanced ultrasound (baseline image)*—The lesion of interest was imaged for 15 seconds with each of the following techniques: fundamental B mode, tissue harmonic B mode, color Doppler, and power Doppler. Afterward, the whole liver was scanned, first in fundamental B mode and then in tissue harmonic B-mode.

*CEUS*—Phase-modulation harmonic mode was used for both vascular and Kupffer phase imaging (mechanical index, 0.3–0.5; frame rate, 8–10 frames/s; transmitting frequency, 1.5–2 MHz). The focus was set below the lesion of interest for vascular phase imaging and at 4–8 cm for the left lobe and 8–10 cm for the right lobe for Kupffer phase imaging. The lesion of interest was imaged from 15 seconds before injection to 1 minute after injection (vascular phase imaging). No further scanning was performed until the Kupffer phase imaging, which was begun 10 minutes after injection. The whole liver was scanned twice with the same protocol as for unenhanced ultrasound.

#### Dynamic CT

Dual-phase dynamic contrast-enhanced studies were performed with helical CT or MDCT. Twelve centers used MDCT and three centers used helical CT. The imaging conditions were not standardized for this study because DCT was performed before enrollment but had been optimized by the respective centers with a mean slice thickness of  $6.9 \pm 2.0$  (SD) mm (range, 2–10 mm). DCT was performed within the month before enrollment for malignant tumors and within 3 months before enrollment for benign tumors. These images were provided for review by the blinded readers.

#### Reference Standard

The reference standard procedures, which had been performed by onsite investigators before study enrollment, included diagnostic imaging

with unenhanced ultrasound and DCT, acquisition of relevant clinical information such as history or existing disorder, and assessment of clinical and biochemical biomarkers. If necessary, dynamic MRI, angiography, or pathologic examination was added.

For characterization, the disease diagnosis was changed when it was believed it would be changed after CEUS and it was confirmed during treatment, or it was changed in the process of treatment during this study period. The disease diagnosis was changed in eight cases, including three cases influenced by CEUS findings. Seven of the eight cases were confirmed at histologic examination of specimens obtained at biopsy or surgery, and one case was confirmed in follow-up. For detection, the number and size of the lesions were recorded by onsite investigators on the basis of findings at unenhanced ultrasound, DCT, or other procedure before enrollment and were used as the reference standards. Patients with newly detected lesions visible only with CEUS underwent follow-up by onsite investigators for 3 months. To confirm whether a lesion was a true lesion, onsite investigators used techniques such as DCT, contrast-enhanced MRI, angiography, biopsy, surgery, or a combination of these procedures, except for unenhanced ultrasound and CEUS.

#### Image Reading

Two readings were performed: an unblinded reading by onsite investigators who had access to all clinical and imaging information and an offsite reading by blinded reviewers. Three blinded reviewers for ultrasound and another three blinded reviewers for DCT were selected from specialists in the field who were independent of the onsite investigators and the coordinating investigator. Unenhanced ultrasound and CEUS videotapes for readings by blinded reviewers were made after enrollment, whereas DCT images were obtained before enrollment. Patient and site identification data were removed from the ultrasound videotapes and CT images. The ultrasound videotapes and CT images then were randomized into three equal portions. Each reader reviewed one third of the total number of cases.

Before evaluation, the three reviewers received training to maintain consistency in the evaluation criteria. For confirmation of reliability after the training, each reader independently evaluated ultrasound videotapes and CT images from 20 cases that had been randomized and from which identifying information was removed. In the characterization assessment, the rates of complete agreement on unenhanced ultrasound, CEUS, and DCT findings among the three reviewers were 85%, 90%, and 90%. In detection assessment, the

rates were 95%, 90%, and 90%. These percentages suggest that interobserver reliability was ensured.

The blinded reviewers assessed the images without clinical information and without knowledge of the results of the onsite evaluation. For characterization with ultrasound, the blinded reviewers interpreted unenhanced ultrasound videotapes depicting only the lesion of interest in each patient separately from tapes containing the vascular phase of CEUS. For detection with ultrasound, the reviewers interpreted unenhanced ultrasound videotapes containing only whole liver scans for each patient separately from those containing the Kupffer phase of CEUS. For CT, the reviewers read CT images containing only slices depicting the lesion of interest for characterization. CT images of all liver slices were used for detection.

In the characterization assessments, the reviewers classified their diagnoses into five categories: HCC, hepatic metastasis, hemangioma, other benign lesion, and other malignant lesion. In addition, the reviewers of ultrasound images reported their degree of confidence in their diagnoses as definite, probable, or suspect. In detection, the reviewers of both ultrasound and DCT images recorded the location and size of the lesions.

#### Efficacy Evaluation

The results of the assessments by the blinded reviewers with each technique (unenhanced ultrasound, CEUS, and DCT) were compared with reference standard findings by the onsite investigators. For evaluation of characterization efficacy, the rates of correct diagnoses for the various lesion types were assessed and compared for unenhanced ultrasound, CEUS, and DCT. Sensitivity and specificity were calculated for correct classification of lesions as malignant or benign. Degree of confidence in the diagnosis was compared between unenhanced ultrasound and CEUS. For evaluation of detection efficacy, the numbers of patients in whom the number of lesions detected by blinded reviewers was less than, equal to, or more than that detected with the reference standard were calculated for unenhanced ultrasound, CEUS, and DCT and compared. In addition, the numbers of lesions detected by blinded reviewers were used to compare efficacy between methods. Efficacy in terms of detection of different types of lesions and of detection of lesions in various size categories was evaluated in a similar manner. In the cases of patients whose treatment strategy was changed on the basis of information from CEUS, the reasons for doing so were recorded.

#### Safety Evaluation

Safety was evaluated by the onsite investigators. Clinical chemistry variables and vital signs were

assessed immediately before and within 24 hours after injection. Patients were observed for adverse events for 72 hours after injection, and the severity and causes of the events were assessed. Serious adverse events were observed for 7 days. Severity criteria were as follows: mild, temporary and easily tolerable; moderate, interfering with normal activities; and severe, completely preventing normal activities.

#### Statistical Analysis

For assessment of characterization efficacy, the McNemar test was used to compare the rates of correct diagnosis of lesions for unenhanced ultrasound, CEUS, and DCT. For assessment of detection efficacy, Wilcoxon's signed rank test was used to compare the lesion detection rates obtained with unenhanced ultrasound, CEUS, and DCT. For all tests,  $p < 0.05$  was considered to indicate a statistically significant difference. A statistical software package (SAS version 8.2, SAS) was used for the statistical analyses.

## Results

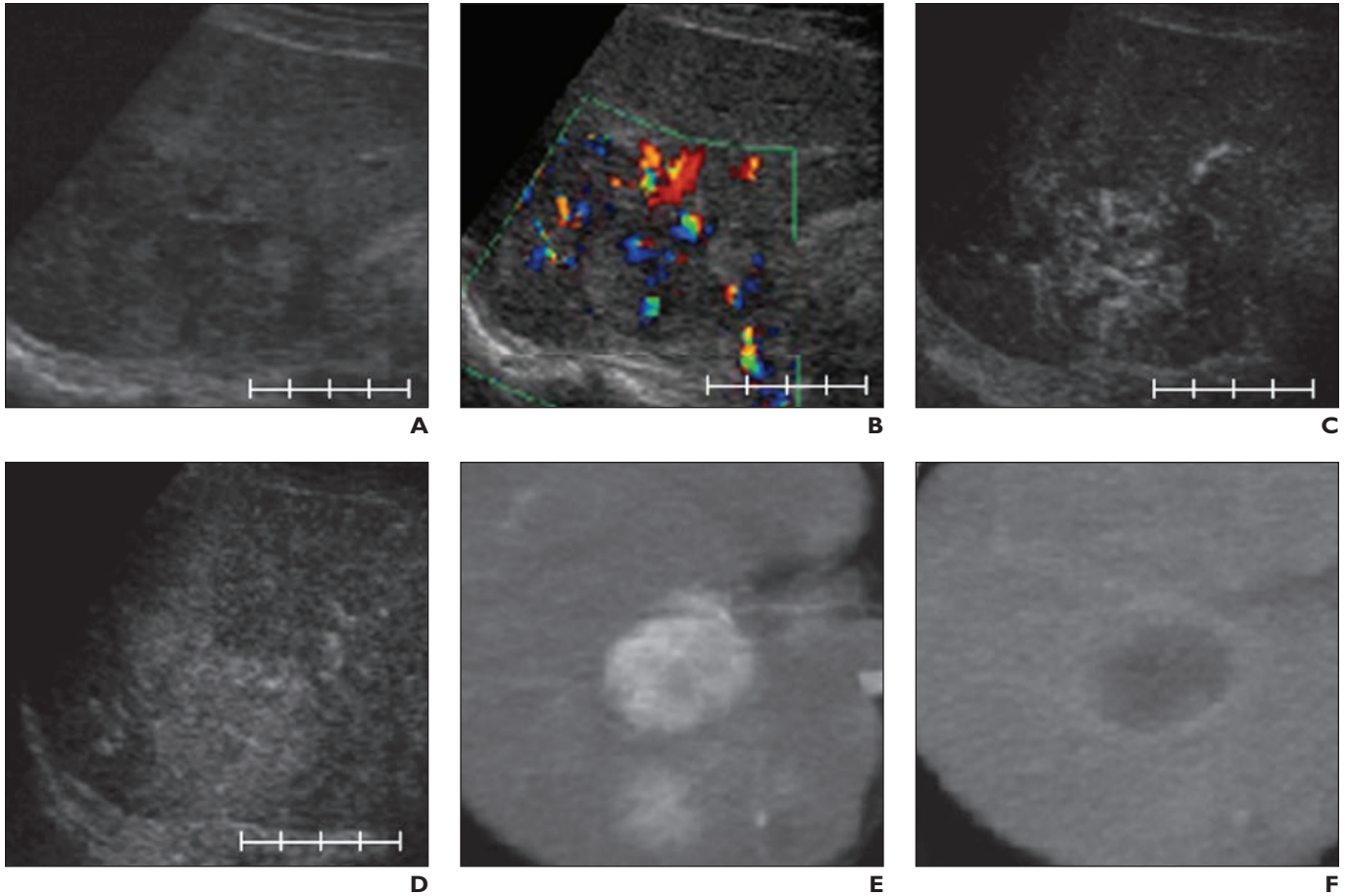
### Characterization

Different types of focal lesions had different patterns of enhancement on vascular phase images. Typical enhancement patterns of HCC, metastasis, and hemangioma on CEUS and DCT images are shown in Figures 1–3. In all cases, CEUS images were adequate for assessment. In no case was lesion contrast missing owing to artifacts from the microbubbles.

As shown in Table 1, the overall rate of correct diagnosis of lesions by the blinded reviewers significantly improved from 68.4% for unenhanced ultrasound to 88.9% for CEUS ( $p < 0.001$ ). In addition, the overall rate of correct diagnosis with CEUS was significantly higher than that with DCT (80.5%) ( $p = 0.008$ ). In classification of the lesions into the five types, the rates of correct diagnosis of HCC, metastasis, and hemangioma were significantly higher for CEUS than for unenhanced ultrasound ( $p < 0.001$ ,  $p = 0.002$ , and  $p = 0.025$ ). In particular, all 17 cases of hemangioma were correctly diagnosed with CEUS (100%). The performance of CEUS in the correct diagnosis of metastasis was superior to that of DCT, but no significant differences were evident for other types of lesions.

In terms of correct classification of lesions as malignant or benign, the overall accuracy and sensitivity significantly improved from 86.3% and 89.0% for unenhanced ultrasound to 97.4% and 98.8% for CEUS (both  $p < 0.001$ ) (Table 2). In contrast, no significant

## Ultrasound of Focal Liver Lesions



**Fig. 1**—75-year-old man with hepatocellular carcinoma. Scale bar = 4 cm.

**A**, B-mode ultrasound image shows mosaic speckle pattern in tumor.

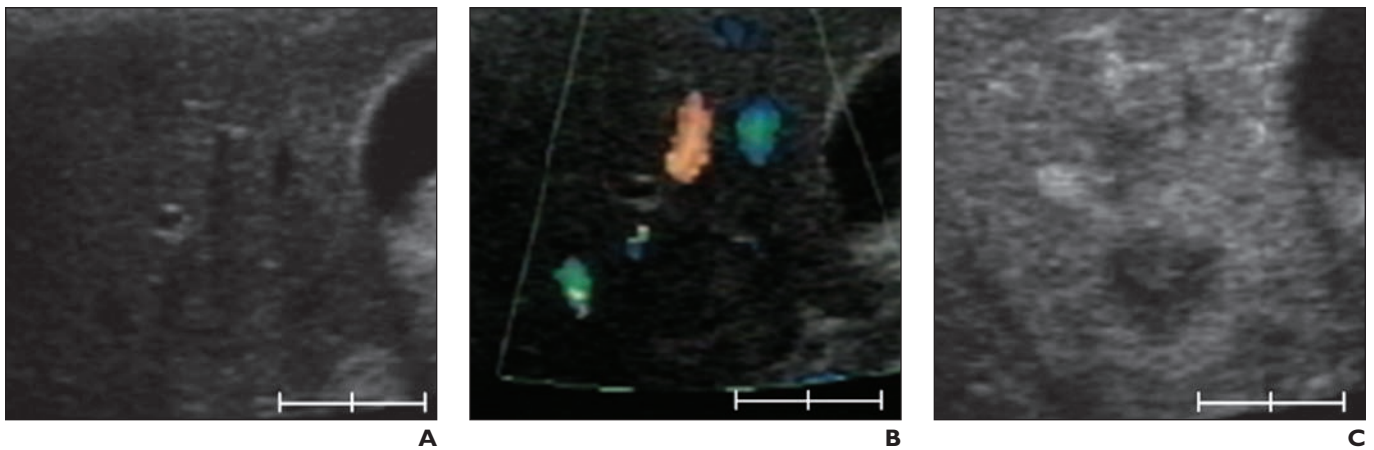
**B**, Color Doppler ultrasound image shows increased vascularity in tumor.

**C**, Vascular phase perflubutane-enhanced ultrasound image shows fine tumor vessels.

**D**, Late vascular phase perflubutane-enhanced ultrasound image shows homogeneously enhanced perfusion in tumor 20 seconds after contrast injection.

**E**, Arterial phase dynamic CT image shows heterogeneous staining of tumor.

**F**, Portal venous phase dynamic CT image shows low-attenuation area with ringlike enhancement.



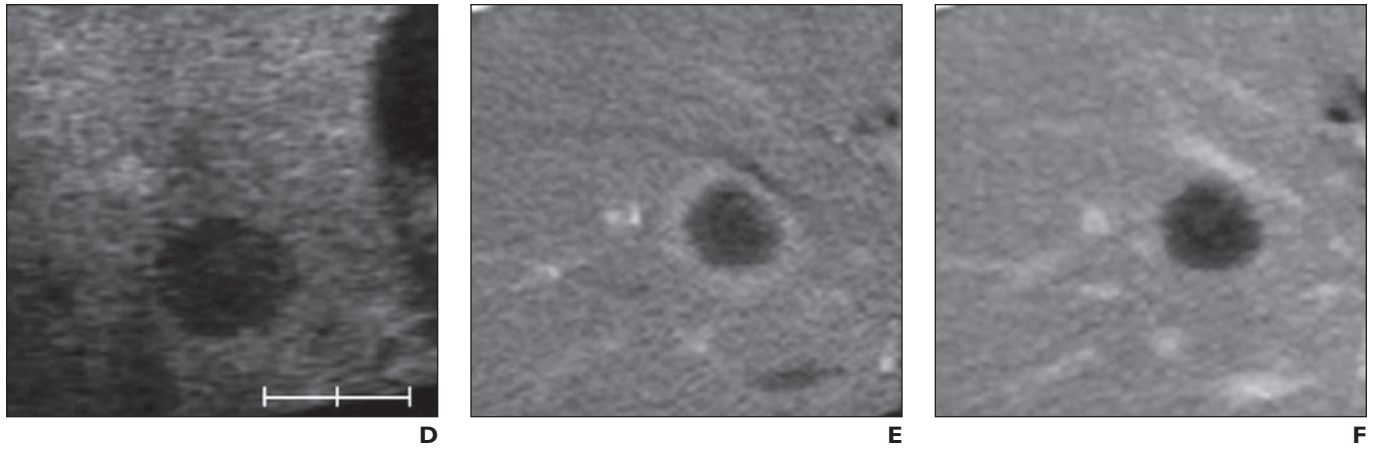
**Fig. 2**—59-year-old woman with liver metastasis. Scale bar = 2 cm.

**A**, B-mode ultrasound image shows hyperechoic tumor with thick halo and bull's-eye pattern.

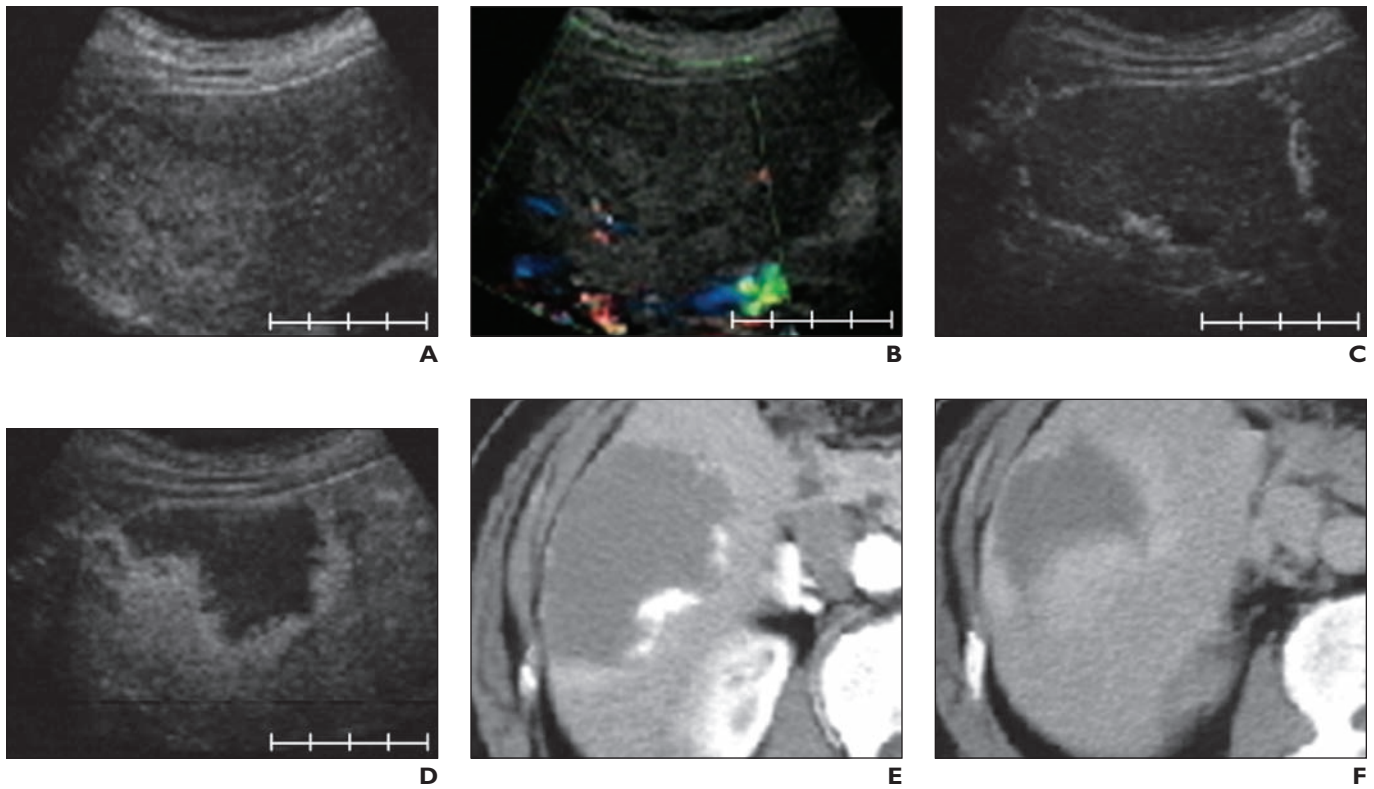
**B**, Color Doppler ultrasound image shows little vascularity in tumor.

**C**, Vascular phase perflubutane-enhanced ultrasound image shows ring enhancement in peripheral portion of tumor.

(Fig. 2 continues on next page)



**Fig. 2 (continued)**—59-year-old woman with liver metastasis. Scale bar = 2 cm.  
**D**, Late vascular phase perflubutane-enhanced ultrasound image shows clearly demarcated washout in tumor.  
**E**, Arterial phase dynamic CT image shows ringlike enhancement in peripheral region of tumor.  
**F**, Late phase dynamic CT image shows weak ring enhancement.



**Fig. 3**—59-year-old man with hemangioma. Scale bar = 4 cm.  
**A**, B-mode ultrasound image shows hyperechoic elliptic mass with unclear delineation.  
**B**, Color Doppler ultrasound image shows little inner vascular signal in tumor.  
**C**, Vascular phase perflubutane-enhanced ultrasound image shows filling-in enhancement in peripheral portion of tumor.  
**D**, Late vascular phase perflubutane-enhanced ultrasound image shows centripetal invasion of filling-in enhancement.  
**E**, Arterial phase dynamic CT image shows filling-in enhancement.  
**F**, Late phase dynamic CT image shows heterogeneous filling-in enhancement.

## Ultrasound of Focal Liver Lesions

**TABLE 1: Rate of Correct Diagnosis in Characterization of Focal Liver Lesions**

Lesion Classification	Unenhanced Ultrasound	CEUS	DCT
Overall	68.4 (130/190)	88.9 (169/190)	80.5 (153/190)
Hepatocellular carcinoma	77.7 (94/121)	92.6 (112/121)	89.3 (108/121)
Metastasis	44.7 (17/38)	78.9 (30/38)	57.9 (22/38)
Hemangioma	70.6 (12/17)	100 (17/17)	94.1 (16/17)
Other benign lesion	44.4 (4/9)	66.7 (6/9)	33.3 (3/9)
Other malignant lesion	60.0 (3/5)	80.0 (4/5)	80.0 (4/5)

Note—Data are percentages. Numbers in parentheses are numbers of patients used for calculation of the percentages. McNemar test results were as follows: Overall—unenhanced ultrasound vs contrast-enhanced ultrasound (CEUS),  $p < 0.001$ ; unenhanced ultrasound vs dynamic CT (DCT),  $p = 0.006$ ; CEUS vs DCT,  $p = 0.008$ . HCC—unenhanced ultrasound vs CEUS,  $p < 0.001$ ; unenhanced ultrasound vs DCT,  $p = 0.016$ . Metastasis—unenhanced ultrasound vs CEUS,  $p = 0.002$ ; CEUS vs DCT,  $p = 0.021$ . Hemangioma—unenhanced ultrasound vs CEUS,  $p = 0.025$ ; unenhanced ultrasound vs DCT,  $p = 0.046$ .

**TABLE 2: Accuracy, Sensitivity, and Specificity in Characterization of Malignant and Benign Lesions**

Characteristic	Unenhanced Ultrasound	CEUS	DCT
Overall accuracy	86.3 (164/190)	97.4 (185/190)	94.7 (180/190)
Sensitivity	89.0 (146/164)	98.8 (162/164)	95.7 (157/164)
Specificity	69.2 (18/26)	88.5 (23/26)	88.5 (23/26)

Note—Data are percentages. Numbers in parentheses are numbers of patients used for calculation of the percentages. Sensitivity and specificity are percentages of malignant and benign lesions correctly diagnosed. McNemar test results were as follows: Accuracy—contrast-enhanced ultrasound (CEUS) vs unenhanced ultrasound,  $p < 0.001$ ; dynamic CT (DCT) vs unenhanced ultrasound,  $p = 0.005$ . Sensitivity—CEUS vs unenhanced ultrasound,  $p < 0.001$ ; DCT vs unenhanced ultrasound,  $p = 0.016$ . Specificity—CEUS vs unenhanced ultrasound,  $p = 0.096$ ; DCT vs unenhanced ultrasound,  $p = 0.132$ .

**Fig. 4**—Degree of confidence scored by blinded reviewers.

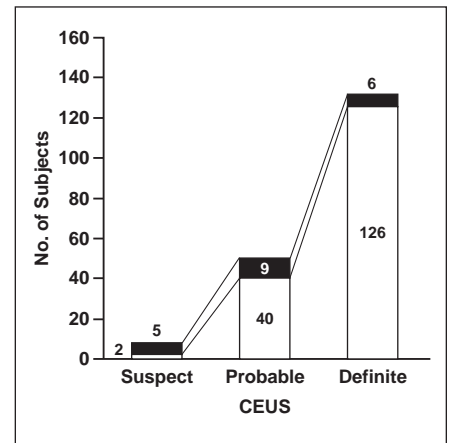
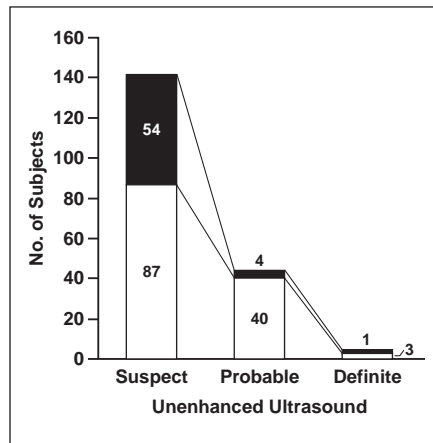
**A** and **B**, Graphs show degree of confidence in diagnoses made with unenhanced ultrasound (**A**) and contrast-enhanced ultrasound (CEUS) (**B**). Disagreement (*black*) indicates that diagnosis by blinded reviewers was not correct. Agreement (*white*) indicates diagnosis by blinded reviewers was correct.

differences in accuracy, sensitivity, or specificity were found between CEUS and DCT.

The level of diagnostic confidence scored by the blinded reviewers was compared between unenhanced ultrasound and CEUS (Fig. 4). The degree of confidence in diagnoses made with unenhanced ultrasound was scored definite in four of 189 cases (2.1%), and one of these diagnoses was incorrect. The number of diagnoses scored definite with CEUS increased to 132 of 189 (69.8%), and 126 of these diagnoses (95.5%) were correct.

### Detection

Metastatic lesions were clearly depicted as contrast defects on CEUS Kupffer phase images (Fig. 5). Table 3 shows the number of patients in whom more, an equal number of, and fewer lesions were detected by the blinded reviewers than by the onsite readers using the reference standard. Using DCT, the blinded reviewers detected more or fewer lesions than were found with the reference standard in similar numbers of patients. Using CEUS, the blinded reviewers detected more lesions approximately twice as often as they detected fewer lesions. The

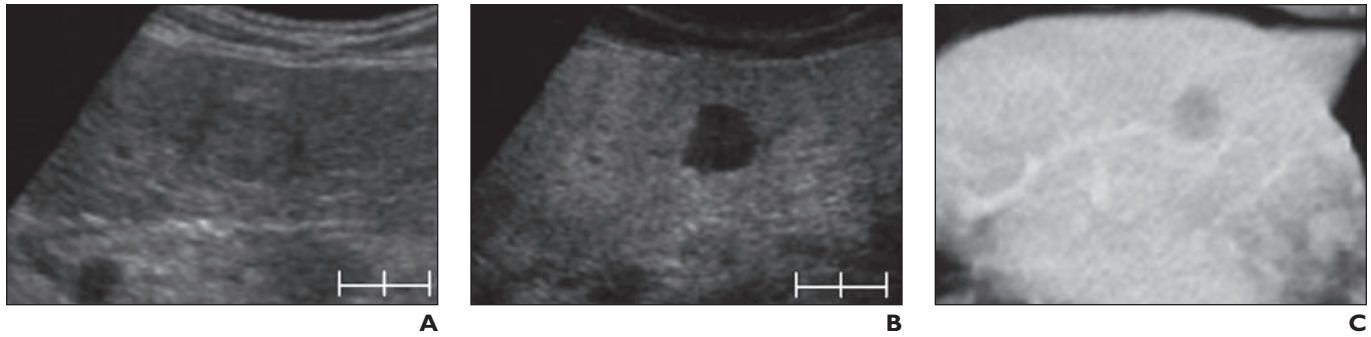


percentages of patients in whom more lesions were detected by the blinded reviewers than were found with the reference standard were 31.9% (61 patients), 18.8% (36 patients), and 13.1% (25 patients) for CEUS, DCT, and unenhanced ultrasound (Table 3). The detection rate with CEUS was significantly higher than that with unenhanced ultrasound and DCT ( $p < 0.001$  and  $p = 0.008$ ).

The number of lesions detected with unenhanced ultrasound, CEUS, and DCT compared with the reference standard was determined for the five types of lesions, and the results are shown in Table 4. The number of lesion detected with CEUS was larger than that with unenhanced ultrasound and DCT. The number

of lesions detected with CEUS (464 lesions) was larger than the number detected with the reference standard (375 lesions). It was particularly evident that the number of metastatic lesions detected with CEUS was significantly larger than the number detected with unenhanced ultrasound ( $p < 0.001$ ) and the number detected with DCT ( $p < 0.001$ ).

In classification of lesions according to size, the number of small lesions ( $\leq 1$  cm) detected with CEUS was significantly larger than the number detected with unenhanced ultrasound ( $p < 0.001$ ) and DCT ( $p = 0.008$ ) (Fig. 6). Furthermore, in classification of metastatic lesions according to size, the number of lesions 1 cm in diameter or smaller



**Fig. 5**—59-year-old man with liver metastasis. Scale bar = 2 cm.  
**A**, Ultrasound image shows heterogeneous hypoechoic mass in lateral segment of left lobe of liver.  
**B**, Perflubutane-enhanced Kupffer phase ultrasound image shows clearly delineated unenhanced area.  
**C**, Late phase dynamic CT image shows slightly low-attenuation area in left lateral segment.

**TABLE 3: Comparison of Numbers of Patients With Lesions Identified by Blinded Reviewers and Those Identified With Reference Standard (n = 191)**

No. of Lesions Identified by Blinded Reviewers	Unenhanced Ultrasound	CEUS	DCT
Exceeded reference standard	13.1 (25)	31.9 (61)	18.8 (36)
Equal to reference standard	57.6 (110)	52.9 (101)	64.4 (123)
Fewer than reference standard	29.3 (56)	15.2 (29)	16.8 (32)

Note—Data are percentages. Numbers in parentheses are numbers of patients. Unenhanced ultrasound and dynamic CT (DCT) but not contrast-enhanced (CEUS) are included in reference standard. Wilcoxon’s signed rank test CEUS vs unenhanced ultrasound,  $p < 0.001$ ; CEUS vs DCT,  $p = 0.008$ .

**TABLE 4: Number of Lesions Detected Classified by Lesion Type**

Classification	Reference Standard	Blinded Reviewers		
		Unenhanced Ultrasound	CEUS	DCT
Hepatocellular carcinoma	245	199	261	257
Metastasis	74	63	147	86
Hemangioma	38	32	37	31
Other benign lesion	11	11	12	10
Other malignant lesion	7	5	7	6
Total	375	310	464	390

Note—For metastasis, contrast-enhanced ultrasound (CEUS) vs unenhanced ultrasound,  $p < 0.001$ ; contrast-enhanced ultrasound vs dynamic CT (DCT),  $p < 0.001$  (Wilcoxon’s signed rank test).

detected with CEUS was significantly larger than the number detected with DCT ( $p < 0.001$ ). No significant difference was found between CEUS and DCT in the detection of lesions larger than 1 cm (Fig. 7).

**Follow-Up of Newly Detected Lesions and Influence on Treatment Strategy**

Among patients with newly visible lesions detected only with CEUS, 16 patients were available for follow-up, and the lesions in 12 patients were confirmed to be true lesions. Confirmation was verified at surgery in four cases, follow-up CT in four cases, follow-up MRI in two cases, follow-up angiography

in one case, and needle biopsy in one case. All lesions in the other four patients were benign. Therefore, 75% (12 of 16) of cases were correctly diagnosed with CEUS. Table 5 shows the cases in which treatment strategy was changed on the basis of the diagnosis reached by the onsite investigators using CEUS. On the basis of information obtained on vascular or Kupffer images, the treatment strategy changed for 13 patients (6.8%).

**Safety**

No deaths, serious or severe adverse events were found in this study. The incidence of adverse events was 49.2% (95% confidence lim-

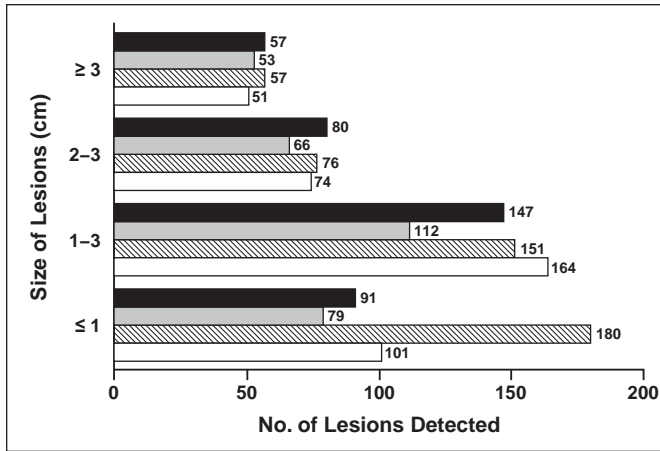
its, 42.2%, 56.3%) (95 of 193 cases). Events with an incidence greater than 2% are shown in Table 6. The incidence of adverse drug reactions was 10.4% (95% confidence limits, 6.1%, 14.7%) (20 of 193 cases (Table 7). All adverse drug reactions were mild.

**Discussion**

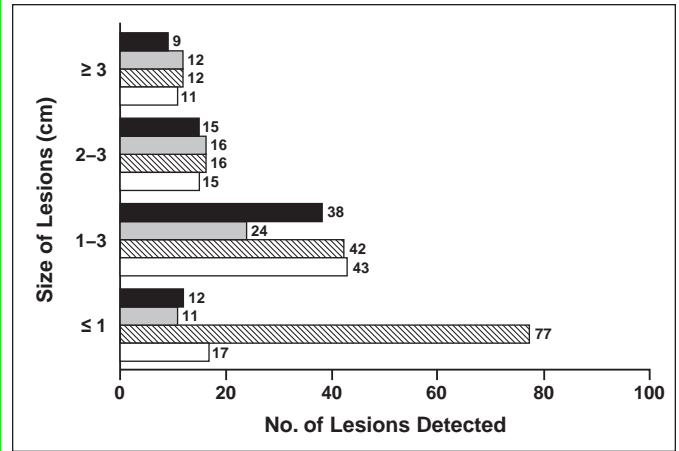
The efficacy of CEUS with perflubutane microbubbles in the characterization and detection of lesions was assessed and compared with that of unenhanced ultrasound and DCT. Characterization of focal liver lesions relies on well-known vascular enhancement patterns at DCT and dynamic MRI, which are the standard methods of diagnosis [20]. Contrast enhancement with perfluorochemical microbubble agents in nonlinear ultrasound imaging, such as phase-modulation harmonic mode, has been found to be efficacious in various studies [21]. Because of the high temporal and spatial resolution of sonography, CEUS can depict the arterial perfusion characteristics of liver lesions and depict fine tumor vasculature. DCT has poorer performance than CEUS.

Differences in contrast enhancement patterns among lesion types have been well studied with several perfluorochemical microbubble agents, and CEUS has had high accuracy in characterization of lesions [22, 23]. Because contrast effects similar to those of other perfluorochemical agents are observed at CEUS with perflubutane microbubbles, it is not surprising that the accuracy of CEUS is higher than that of DCT. For example, although the number of cases was limited, the accuracy of CEUS in the diagnosis of hemangioma was 100%. Real-time CEUS depicted the typical enhancement pattern of hemangioma—namely, peripheral globular pooling of contrast material (cotton-wool appearance) followed by gradual perfusion of the entire

## Ultrasound of Focal Liver Lesions



**Fig. 6**—Graph shows number of lesions classified according to lesion size detected by blinded reviewers using unenhanced ultrasound (*gray*), contrast-enhanced ultrasound (CEUS) (*striped*), and dynamic CT (*white*) and by onsite investigators using reference standard (*black*). Wilcoxon's signed rank test for lesions 1 cm or smaller, CEUS vs dynamic CT,  $p = 0.008$ ; CEUS vs unenhanced ultrasound,  $p < 0.001$ ; CEUS vs reference standard,  $p = 0.001$ .



**Fig. 7**—Graph shows number of metastatic lesions classified according to lesion size detected by blinded reviewers using unenhanced ultrasound (*gray*), contrast-enhanced ultrasound (CEUS) (*striped*), and dynamic CT (*white*) and by onsite investigators using reference standard (*black*). Wilcoxon's signed rank test for lesions 1 cm or smaller, CEUS vs dynamic CT,  $p < 0.001$ ; CEUS vs unenhanced ultrasound,  $p < 0.001$ ; CEUS vs reference standard,  $p < 0.001$ .

**TABLE 5: Changes in Treatment Strategy After Contrast-Enhanced Ultrasound Diagnosis**

Treatment Planned Before Contrast-Enhanced Ultrasound	Treatment Planned After Contrast-Enhanced Ultrasound	No. of Patients
Radiofrequency ablation	Surgery	3
Radiofrequency ablation (RFA)	RFA (additional ablation)	2
Observation (benign lesion)	Surgery (malignant lesion)	2
Surgery (malignant lesion)	Observation (benign lesion)	1
Transcatheter arterial chemoembolization	Chemotherapy	1
Radiotherapy	Chemotherapy	1
Percutaneous ethanol injection therapy	Additional percutaneous ethanol injection therapy	1
Observation	Further examination	1
Bile duct stent	Transcatheter arterial chemoembolization	1

lesion. Compared with unenhanced ultrasound, CEUS not only had approximately 20% greater overall accuracy but also was associated a higher degree of diagnostic confidence. Therefore, CEUS with perflubutane microbubbles is likely to be useful as a standard method of diagnosis and one that is comparable with DCT.

In terms of lesion detection, CEUS depicted more lesions than did DCT, many of which were small metastatic lesions ( $\leq 1$  cm). Because of the high specificity of uptake of perflubutane microbubbles by Kupffer cells in normal parenchyma [16–18], malignant lesions that lack Kupffer cells are negatively enhanced. This characteristic, coupled with the higher spatial resolution of ultrasound, may explain the increased efficacy of CEUS

in the detection of small lesions. SH U 508A (Levovist, Bayer Schering Pharma), an air-based microbubble agent, has been reported to have a parenchyma-specific contrast effect similar to that of perflubutane microbubbles, and this effect has been useful in detecting lesions [24, 25]. The parenchyma-specific contrast effect of SH U 508A is observed several minutes after injection, but it is effective only when imaging is performed at high acoustic power, and the effect is transient. Because imaging with SH U 508A entails destruction of microbubbles, visualization of the whole liver is limited to a single scan [26]. In contrast, because imaging with perflubutane microbubbles is performed at lower acoustic power without destruction of microbubbles, repeated scanning of the whole

**TABLE 6: Adverse Events (n = 193)**

Event	No. of Patients
Fever	16 (8.3)
Nausea	13 (6.7)
Diarrhea	12 (6.2)
Malaise	11 (5.7)
Lumbar pain	10 (5.2)
Headache	9 (4.7)
Increased blood pressure	9 (4.7)
Abdominal pain	9 (4.7)
Thirst	7 (3.6)
Pain	7 (3.6)
Vomiting	7 (3.6)
Flank pain	6 (3.1)
Feeling of warmth	5 (2.6)
Enlarged feeling of abdomen	5 (2.6)
Omalgia	4 (2.1)
Dizziness	4 (2.1)
Decreased blood pressure	4 (2.1)
Epigastric pain	4 (2.1)
Injection site pain	4 (2.1)
Any adverse event	95 (49.2)

Note—Events with an incidence greater than 2% are listed. Some patients had more than one event. Values in parentheses are percentages.

liver can be accomplished, as in our study. This capability may help operators reduce the number of missed lesions. Another technique that entails the use of Kupffer phase



**TABLE 7: Adverse Drug Reactions (n = 193)**

Event	No. of Patients
Albuminuria	3 (1.6)
Diarrhea	3 (1.6)
Neutropenia	2 (1.0)
Itching	1 (0.5)
Rash	1 (0.5)
Eruption	1 (0.5)
Headache	1 (0.5)
Stupor	1 (0.5)
Hypertension	1 (0.5)
Redness	1 (0.5)
Vomiting	1 (0.5)
Thirst	1 (0.5)
Increased lactate dehydrogenase level	1 (0.5)
Glycosuria	1 (0.5)
Peripheral ischemia	1 (0.5)
Thrombocytopenia	1 (0.5)
Hot flashes	1 (0.5)
Injection site pain	1 (0.5)
Any adverse reaction	20 (10.4)

Note—Values in parentheses are percentages. Some patients had more than one reaction.

imaging is contrast MRI with superparamagnetic iron oxide, which is also taken up by Kupffer cells [27, 28]. Although further studies are needed to compare CEUS with perflubutane microbubbles and MRI with superparamagnetic iron oxide, CEUS has the advantage of higher temporal and spatial resolution.

Most malignant tumors of the liver are HCC and metastatic lesions. HCC is one of a few malignant tumors in which the etiologic and pathogenic processes are understood and groups at high risk are well known. Chronic viral hepatitis leads to cirrhosis, which is a predisposing factor for HCC [29, 30]. This course is predominant in Asia. For early detection and treatment, it is recommended that these high-risk groups undergo ultrasound and DCT every 3 and 6 months, respectively [31]. Other groups at high risk are patients with alcoholic liver disease and, increasingly, those with fatty infiltration (non-alcoholic steatohepatitis) [32], which predominate in other parts of the world. Thus the need for early diagnosis of HCC is increasing. The liver also is a frequent site of metastasis. Strategies for the management of

primary tumors and the prognosis are influenced by the absence or presence of hepatic metastasis, and early detection of these lesions is important.

Although it is the standard method of diagnosis of both types of liver tumors, DCT has limitations. First, radiation-induced cancer from CT examinations is becoming a major issue [33], and fewer CT examinations are being recommended. CT should be used only when the benefits outweigh the risks. Second, the sensitivity of DCT with helical CT in the detection of small metastatic lesions of the liver ( $\leq 1$  cm) is 30–50% [34]. DCT with MDCT at collimation less than 5 mm does not have greater sensitivity for lesions 1.5 cm or smaller [35]. In this study, CEUS with perflubutane microbubbles was superior to DCT in both characterization and detection of focal liver lesions, especially in the detection of small hepatic metastatic lesions. The treatment of 13 of 191 patients (6.8%) was changed on the basis of the CEUS diagnosis. This finding suggests that current diagnostic procedures have room for improvement and that CEUS with perflubutane microbubbles may be an alternative to DCT.

In this study, patients with unenhanced ultrasound images of adequate quality were enrolled, and all the lesions imaged with unenhanced ultrasound were enhanced at CEUS without artifacts such as shadowing. This finding suggests that perflubutane microbubbles cause fewer artifacts. This effect may be attributed to the fact that the higher mechanical index can be applied for perflubutane microbubbles than for other perfluorochemical microbubbles, such as aqueous suspension of phospholipid-stabilized microbubbles filled with sulfur hexafluoride (SonoVue, Bracco) and perflutren (Definity, Lantheus Medical Imaging) owing to higher resistance to pressure [14].

The incidences of adverse events and adverse drug reactions were self-limited over the period of observation and were 49.2% and 10.4%, respectively. The relatively high incidence of adverse events can be attributed to adverse events caused by the primary disease, cancer, itself and by treatments and examinations after administration of perflubutane microbubbles. All adverse drug reactions were mild in intensity, and none was peculiar to perflubutane microbubbles. Therefore, the findings suggest that perflubutane microbubbles is a safe contrast agent.

A limitation of this study was potential bias affecting the blinded readings of DCT imag-

es because DCT was part of the reference standard. Despite this possible bias in favor of DCT, CEUS was more accurate than DCT in lesion characterization. This finding suggests that CEUS has potential as a diagnostic alternative to DCT for lesion characterization. Other limitations regarding DCT were that MDCT was not used at all centers and the slice thickness varied from 2 to 10 mm among the centers and was not standardized, although all were within routine CT protocols.

Another limitation was that not all newly detected lesions were followed up. Compared with the reference standard, 89 new lesions were detected only with CEUS in 61 patients. The onsite investigators tried to conduct follow-up, and 12 of 16 cases were confirmed to be true lesions. This finding suggests that CEUS has high potential in the detection of new true lesions. An additional limitation was the extent of the overall safety assessment. Although no serious adverse reactions, such as anaphylactic reaction or shock, were observed with perflubutane microbubbles in the 193 patients in this study or in more than 2,000 patients in clinical trials in the United States and Europe (unpublished data), further careful safety assessments are needed.

We conclude that compared with unenhanced ultrasound and DCT, CEUS with perflubutane microbubbles had better diagnostic efficacy in the characterization and detection of focal liver lesions with no substantial adverse drug reactions. CEUS with perflubutane microbubbles has potential as a diagnostic alternative to DCT in the care of patients with known or suspected focal liver lesions.

#### Acknowledgments

We thank K. Koito, T. Iwasaki, K. Sasaki, Y. Mizuguchi, N. Izumi, N. Ueno, T. Kumada, H. Gotoh, F. Urano, Y. Horiguchi, Y. Matsuda, S. Tanaka, Y. Kinoshita, M. Sata, S. Matsutani, M. Kudo, T. Hirai, A. Kono, A. Tanimoto, and T. Ichikawa, for data collection and assessment.

The 15 enrolling centers were Sapporo Medical University Hospital, Sapporo; Tohoku University Hospital, Sendai; National Cancer Center, Tokyo; Showa University Hospital, Tokyo; Tokyo Medical University, Tokyo; Musashino Red Cross Hospital, Musashino; Yokohama City University Hospital, Yokohama; Nagoya University Hospital, Nagoya; Fujita Health University Hospital, Toyoake; Toyohashi Municipal Hospital, Toyohashi; Ogaki Municipal Hospital, Ogaki; Osaka Medical Center for Cancer and

## Ultrasound of Focal Liver Lesions

Cardiovascular Diseases, Osaka; Otemae Hospital, Osaka; Shimane University Hospital, Izumo; and Kurume University Hospital, Kurume.

### References

1. Goldberg BB, Liu JB, Forsberg F. Ultrasound contrast agents: a review. *Ultrasound Med Biol* 1994; 20:319–333
2. Cosgrove D. Echo enhancers and ultrasound imaging. *Eur J Radiol* 1997; 26:64–76
3. Chomas JE, Dayton P, Allen J, Morgan K, Ferrara KW. Mechanisms of contrast agent destruction. *IEEE Trans Ultrason Ferroelectr Freq Control* 2001; 48:232–248
4. Kim TK, Han JK, Kim AY, Choi BI. Limitations of characterization of hepatic hemangiomas using a sonographic contrast agent (Levovist) and power Doppler ultrasonography. *J Ultrasound Med* 1999; 18:737–743
5. Klibanov AL, Ferrara KW, Hughes MS, et al. Direct video-microscopic observation of the dynamic effects of medical ultrasound on ultrasound contrast microspheres. *Invest Radiol* 1998; 33:863–870
6. Schutt EG, Klein DH, Mattrey RM, Riess JG. Injectable microbubbles as contrast agents for diagnostic ultrasound imaging: the key role of perfluorochemicals. *Angew Chem Int Ed Engl* 2003; 42:3218–3235
7. Lindner JR. Microbubbles in medical imaging: current applications and future directions. *Nat Rev Drug Discov* 2004; 3:527–532
8. de Jong N, Frinking PJ, Bouakaz A, Ten Cate FJ. Detection procedures of ultrasound contrast agents. *Ultrasonics* 2000; 38:87–92
9. Metoki R, Moriyasu F, Kamiyama N, et al. Quantification of hepatic parenchymal blood flow by contrast ultrasonography with flash-replenishment imaging. *Ultrasound Med Biol* 2006; 32:1459–1466
10. Burns PN, Wilson SR, Simpson DH. Pulse inversion imaging of liver blood flow: improved method for characterizing focal masses with microbubble contrast. *Invest Radiol* 2000; 35:58–71
11. Brannigan M, Burns PN, Wilson SR. Blood flow patterns in focal liver lesions at microbubble-enhanced US. *RadioGraphics* 2004; 24:921–935
12. Leen E, Ceccotti P, Kalogeropoulou C, Angerson WJ, Moug SJ, Horgan PG. Prospective multicenter trial evaluating a novel method of characterizing focal liver lesions using contrast-enhanced sonography. *AJR* 2006; 186:1551–1559
13. Nicolau C, Vilana R, Catalá V, et al. Importance of evaluating all vascular phases on contrast-enhanced sonography in the differentiation of benign from malignant focal liver lesions. *AJR* 2006; 186:158–167
14. Sontum PC. Physicochemical characteristics of Sonazoid, a new contrast agent for ultrasound imaging. *Ultrasound Med Biol* 2008; 34:824–833
15. Watanabe R, Matsumura M, Chen CJ, Kaneda Y, Ishihara M, Fujimaki M. Gray-scale liver enhancement with Sonazoid (NC100100), a novel ultrasound contrast agent: detection of hepatic tumors in a rabbit model. *Biol Pharm Bull* 2003; 26:1272–1277
16. Yanagisawa K, Moriyasu F, Miyahara T, Miyata Y, Iijima H. Phagocytosis of ultrasound contrast agent microbubbles by Kupffer cells. *Ultrasound Med Biol* 2007; 33:318–325
17. Watanabe R, Matsumura M, Munemasa T, Fujimaki M, Suematsu M. Mechanism of hepatic parenchyma-specific contrast of microbubble-based contrast agent for ultrasonography: microscopic studies in rat liver. *Invest Radiol* 2007; 42:643–651
18. Kindberg GM, Tolleshaug H, Roos N, Skotland T. Hepatic clearance of Sonazoid perfluorobutane microbubbles by Kupffer cells does not reduce the ability of liver to phagocytose or degrade albumin microspheres. *Cell Tissue Res* 2003; 312:49–54
19. Forsberg F, Piccoli CW, Liu JB, et al. Hepatic tumor detection: MR imaging and conventional US versus pulse-inversion harmonic US of NC100100 during its reticuloendothelial system-specific phase. *Radiology* 2002; 222:824–829
20. Winterer JT, Kotter E, Ghanem N, Langer M. Detection and characterization of benign focal liver lesions with multislice CT. *Eur Radiol* 2006; 16:2427–2443
21. Rettenbacher T. Focal liver lesions: role of contrast-enhanced ultrasound. *Eur J Radiol* 2007; 64:173–182
22. Konopke R, Bunk A, Kersting S. The role of contrast-enhanced ultrasound for focal liver lesion detection: an overview. *Ultrasound Med Biol* 2007; 33:1515–1526
23. Quaiá E, Calliada F, Bertolotto M, et al. Characterization of focal liver lesions with contrast-specific US modes and a sulfur hexafluoride-filled microbubble contrast agent: diagnostic performance and confidence. *Radiology* 2004; 232:420–430
24. Albrecht T, Blomley MJ, Burns PN, et al. Improved detection of hepatic metastases with pulse-inversion US during the liver-specific phase of SHU 508A: multicenter study. *Radiology* 2003; 227:361–370
25. Harvey CJ, Blomley MJ, Eckersley RJ, Heckemann RA, Butler-Barnes J, Cosgrove DO. Pulse-inversion mode imaging of liver specific microbubbles: improved detection of subcentimetre metastases. *Lancet* 2000; 355:807–808
26. Blomley MJ, Albrecht T, Cosgrove DO, et al. Improved imaging of liver metastases with stimulated acoustic emission in the late phase of enhancement with the US contrast agent SH U 508A: early experience. *Radiology* 1999; 210:409–416
27. Reimer P, Balzer T. Ferucarbotran (Resovist): a new clinically approved RES-specific contrast agent for contrast-enhanced MRI of the liver—properties, clinical development, and applications. *Eur Radiol* 2003; 13:1266–1276
28. Tanimoto A, Kuribayashi S. Application of superparamagnetic iron oxide to imaging of hepatocellular carcinoma. *Eur J Radiol* 2006; 58:200–216
29. Parikh S, Hyman D. Hepatocellular cancer: a guide for the internist. *Am J Med* 2007; 120:194–202
30. Okita K. Clinical aspects of hepatocellular carcinoma in Japan. *Intern Med* 2006; 45:229–233
31. Kobayashi K, Terasaki S, Matsushita E, Kaneko S. Strategy of early diagnosis. *Kan-Tan-Sui Frontier* 1999; 5:57–59
32. Bruix J, Sherman M. Diagnosis of small HCC. *Gastroenterology* 2005; 129:1364
33. Berrington de González A, Darby S. Risk of cancer from diagnostic x-rays: estimates for the UK and 14 other countries. *Lancet* 2004; 363:345–351
34. Bluemke DA, Sahani D, Amendola M, et al. Efficacy and safety of MR imaging with liver-specific contrast agent: U.S. multicenter phase III study. *Radiology* 2005; 237:89–98
35. Haider MA, Amitai MM, Rappaport DC, et al. Multi-detector row helical CT in preoperative assessment of small (< or = 1.5 cm) liver metastases: is thinner collimation better? *Radiology* 2002; 225:137–142